



Dr. Sok-Chenh Chhean

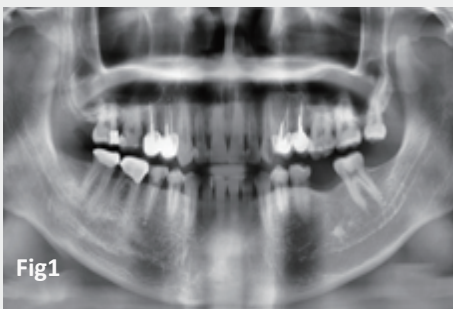
COUNTRY : Cambodia

- DDS (Cambodia), Post-grad in Ortho (South Korea), MSc(Germany), FICD
- Diplomate of Asia Pacific Academy of Implant Dentistry, Taiwan
- Lecturer 1-International University, Cambodia
2-University of Puthisastra, Cambodia
- Clinical Director: Gallery Dental and Aesthetic Clinic, Cambodia

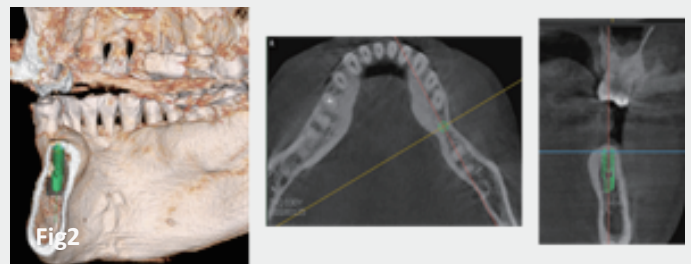
SUBJECT - Single Implant Placement for Missing Tooth #36 Region

CASE DESCRIPTION

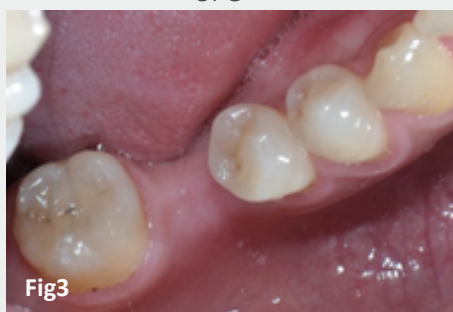- The Cambodian male patient, age 32 years old with good medical condition, complained about missing tooth #36.
- The patient restricted a course of Bone Augmentation.
- Anker SBII 3.5 x 10mm was surgically placed with 1 stage approach.



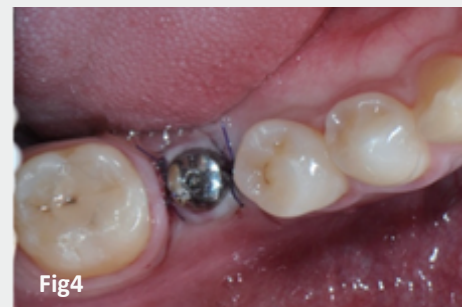11 Feb, 2017
OPG



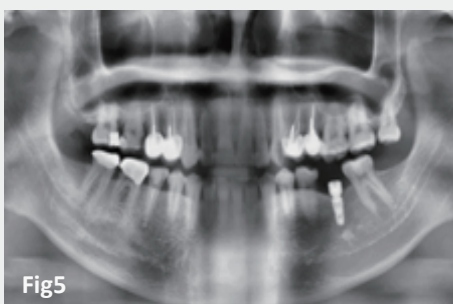
CBCT showed a possible bone morphology for
Implant size 3.5x10mm



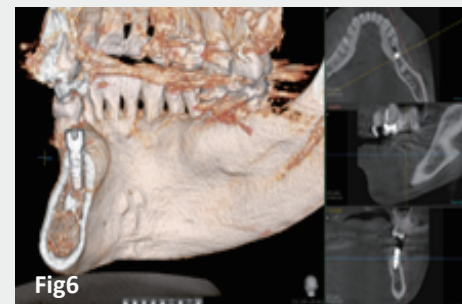
11 Feb, 2017
Photo Intra oral examination



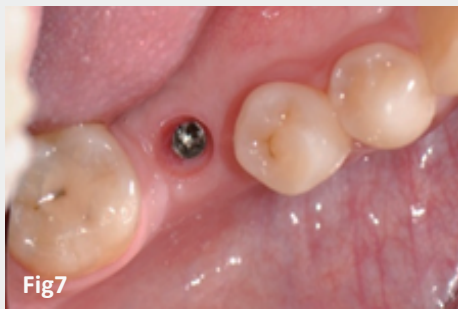15 Feb, 2017
1 stage approach



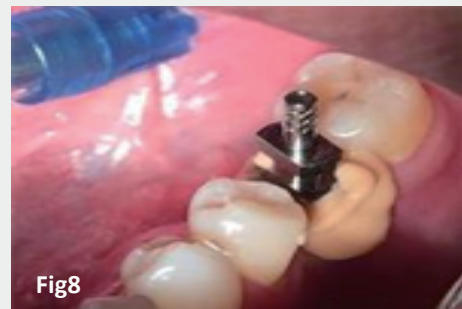OPG: After Implant Placement



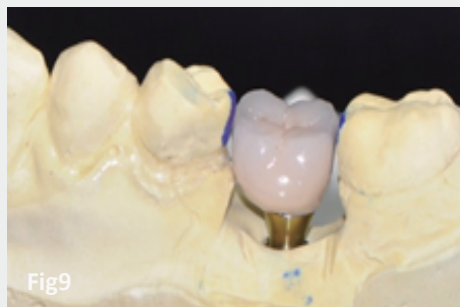
CBCT: After Implant Placement



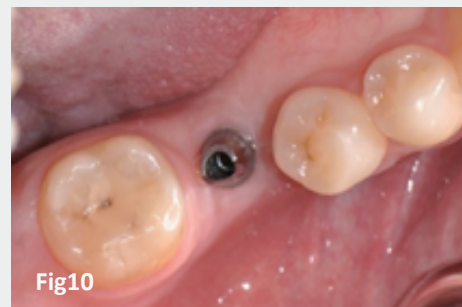10 May, 2017
Nearly 3 months post-operation



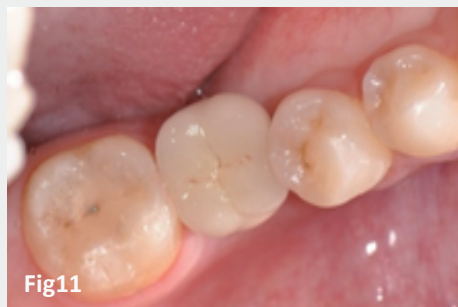10 May, 2017
Open Tray Impression



PFM Cement Retained

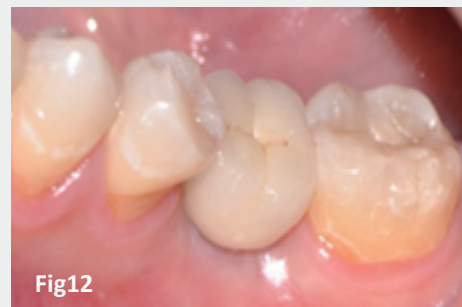

Anker Dual Abutment

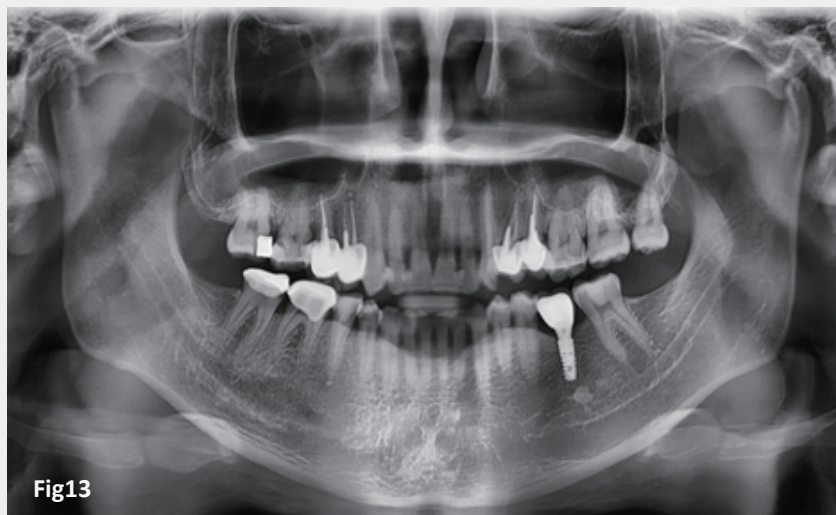

20 May, 2017
Immediate Cementation

Fig2



20 May, 2017
Immediate Cementation



20 May, 2017
OPG after Implant Placement with Prosthesis