



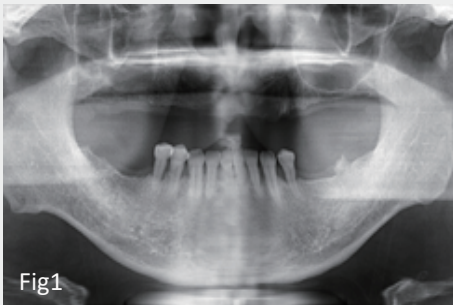
Dr. SHOHEI IKEDA COUNTRY JAPAN

- D.D.S., PhD.: IKEDA DENTAL OFFICE – Chief Dr.
- Showa University, Department of Oral Radiology, Part-time lecturer
- Japanese Society of Oral Implantology, Specialist

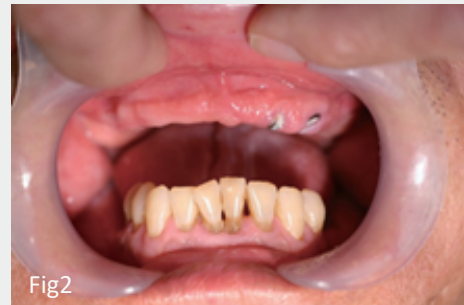SUBJECT - All On X- Concept With Anker Titanium Implant Bar

CASE DESCRIPTION

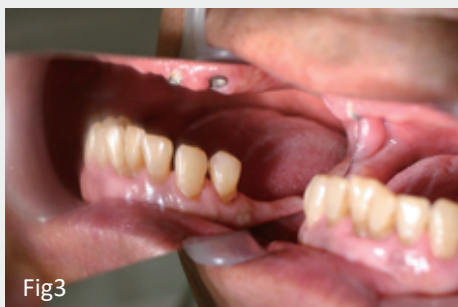65 year-old male with diabetes. Bone quality D2 with moderate alveolar bone resorption. There are no teeth without 23 and 24-C4. Patient has used inadequate -broken edentulous over denture. Moderate gum inflammation. Fitting of titanium flame-work and multi-unit abutment was perfect.



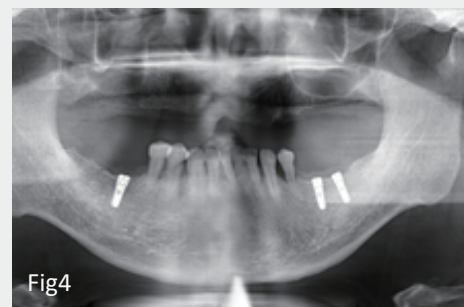
2017. Apr.
First visit



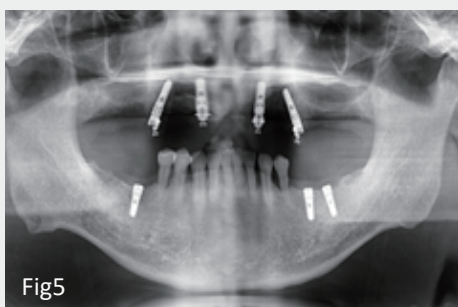
2017. Apr.
Upper jaw preoperative intraoral



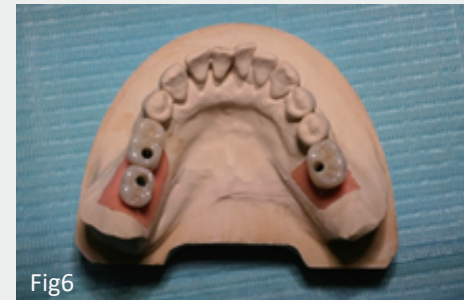2017. Apr.
Lower jaw preoperative intraoral



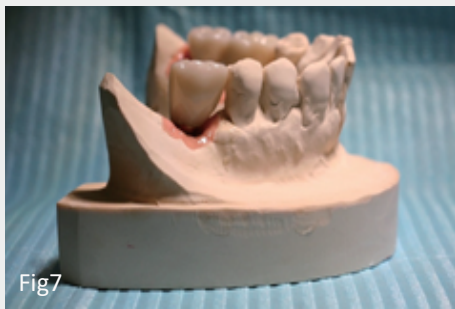2017. May.
Anker implants were inserted on 35, 36, 46



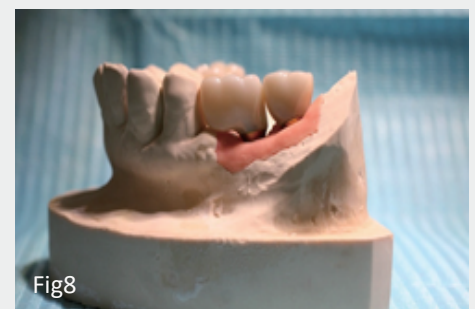2017. Jun.
All on 4- concept on Maxilla



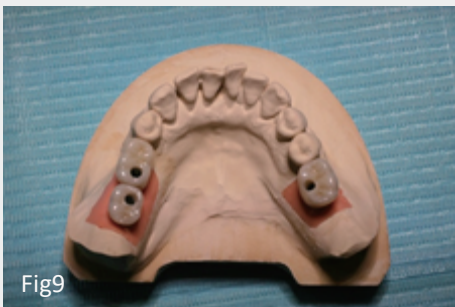Single tooth crown of occlusal findings



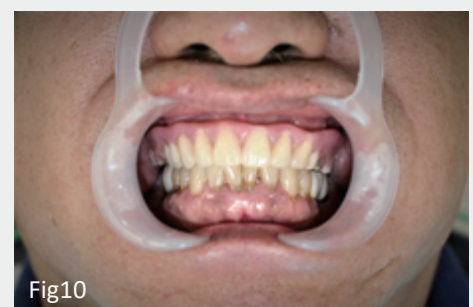Right side findings



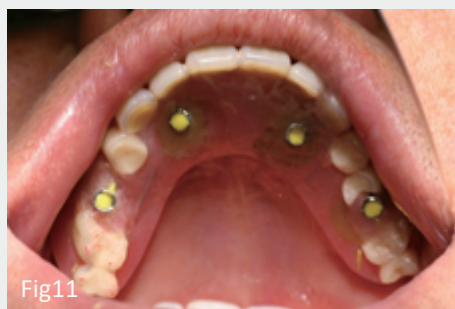Left side findings



2018. Jun.
Panoramic X-ray after Implantation



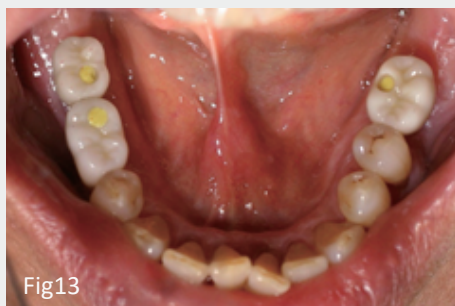2018. Jun.
Intra oral picture- Occlusal view with denture



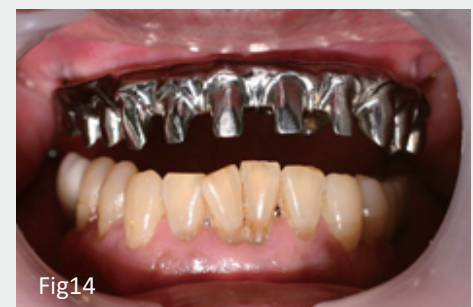First implant bridge was set on All on 4 concept



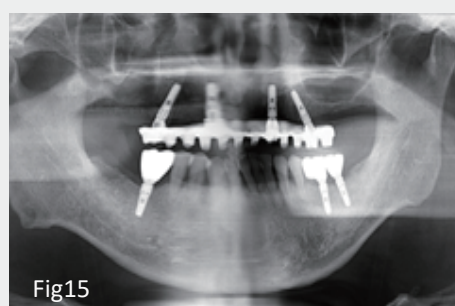
2018. Aug.
Silicon impression was taken



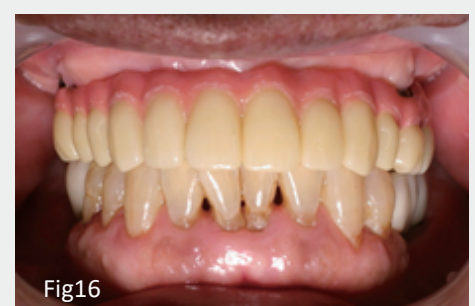2018. Aug.
Zr. Cr. was installed on 36, 35, 46.



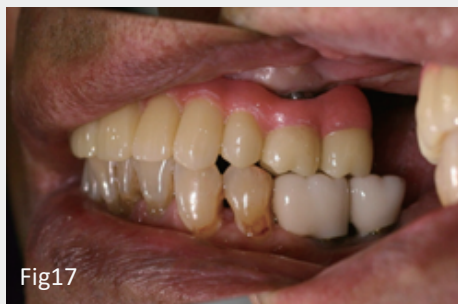2018. Sep.
Titanium frame work fitting



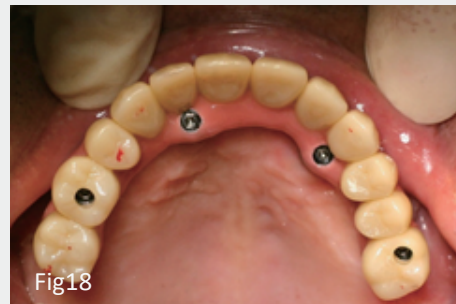2018. Nov.
Titanium frame-work (X-ray)



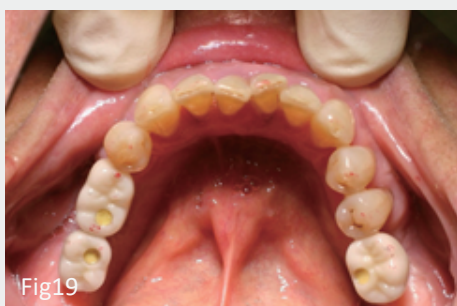2018. Nov.
Denture Completed



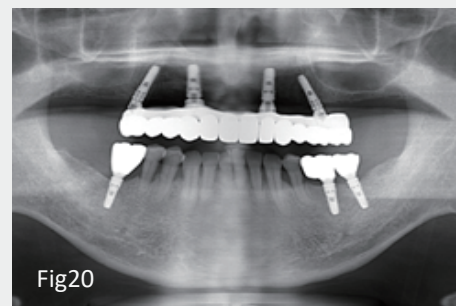
2018. Nov.
Denture Completed



2018. Nov.
Denture Completed



2018. Nov.
Denture Completed



2018. Nov.
Denture Completed (X-ray)

Fig11

Fig12

Fig5

Fig13

Fig14

Fig15

Fig16